
Using fMRI to Examine Central Auditory Plasticity

Deborah A. Hall, Cornelis P. Lanting and Douglas E.H. Hartley

Additional information is available at the end of the chapter

<http://dx.doi.org/10.5772/29929>

1. Introduction

During the last two decades or so, auditory neuroscience has made significant progress in understanding the functional organization of the auditory system in both normal-hearing listeners, patients with sensorineural hearing impairments and/or tinnitus, and following cochlear implantation. Modern brain imaging techniques have made an enormous contribution to that progress by enabling the *in vivo* study of human central auditory function. Since its introduction, magnetic resonance imaging (MRI) has evolved to become one of the most influential methods for investigating non-invasive human brain structure and function. Functional MRI (fMRI) has become the tool of choice for addressing many research questions concerning central auditory plasticity. First, fMRI has good spatial sensitivity and specificity and so can be used to map auditory responses with reasonably fine topographic detail (Logothetis et al., 2001). Second, fMRI is suitable for research use with children, as well as adults. Third, since multiple observations can be made on the same individual, fMRI permits the investigation of longer-term dynamic processes, such as functional plasticity after disease, damage, retraining or therapy. Finally, the need for averaging data across individuals is reduced, further improving the accuracy with which activations can be mapped onto subject-specific brain structure (e.g. Talavage et al., 2004). Despite these advantages, there are significant issues using this technique in certain clinical populations, such as individuals with a cochlear implant (CI). Subsequently, to investigate the effects of CIs on brain reorganization, it is necessary to consider alternative functional imaging methods, such as electroencephalography (e.g. Debener et al., 2008). Moreover, the high level of the scanner acoustic noise can have detrimental effects on central auditory function, patient anxiety and verbal communication between patient and scanner operator (Mechefske et al., 2002). In terms of central auditory function, the scanner acoustic noise can induce increases in the fMRI response of the auditory cortex as well as interfere with the perception of externally presented sound stimuli (Edmister et al., 1999; Hall et al., 1999).

Although functional imaging of the central auditory pathway has not been widely used in Ear, Nose and Throat or Audiology clinics, there is a growing literature on its potential application. Using insights gained from functional imaging research with normal-hearing subjects, we can now transfer the most efficient protocols to study patients with hearing problems. For example, a choice of methods is available for noise reduction and a range of scanning parameters have been optimised to enhance the detection of brain activity.

This chapter discusses some of the theoretical and technical challenges of auditory fMRI and several of the major themes within this field, notably cortical reorganization underpinning tinnitus and deafness. Also we will consider the effect of CIs on the auditory brain, the difficulties associated with the use of conventional imaging methods in CI populations, and potential application of novel techniques, such as near infrared spectroscopy. Sections not only highlight evidence for neuroplasticity within the central auditory system, but also review what is currently known about the involvement and integration of information from other sensory modalities.

2. Challenges and limitations of auditory fMRI

Rather than directly measuring the stimulus- and task-related electrical activity of neurons, fMRI measures indirect changes in the magnetic properties of the blood. Most common methods make use of the blood-oxygen-level-dependent (BOLD) contrast. This technique is based on the increase in signal intensity caused by an increase in oxygen concentration of blood (Ogawa et al., 1990). The functional image represents the spatial distribution of blood oxygenation levels in the brain and the small fluctuations in these levels over time are correlated with the stimulus input or cognitive task.

To detect the magnetic properties of brain tissue, MR scanners operate using three different types of electromagnetic fields: a very high static field generated by a superconducting magnet, time-varying gradient magnetic fields and pulsed radiofrequency (RF) fields. The latter two fields are much weaker than the first, but all pose a number of unique and considerable technical challenges for conducting auditory fMRI research within this hostile environment.

In the first place, the static and time-varying magnetic fields preclude the use of many types of electronic sound presentation equipment, as well as preventing the safe scanning of patients who are wearing listening devices such as hearing aids or implants. Despite the restriction on the materials that can be used in a scanner, a number of different MR-compatible active headphone driving units have been produced for sound delivery. Several audio systems use electrostatic transducers to ensure high performance. Electrostatic headphones generate sound using a conductive diaphragm placed next to a fixed conducting panel. A high voltage polarises the fixed panel and the audio signal passing through the diaphragm rapidly switches between a positive and a negative signal, attracting or repelling it to the fixed panel and thus vibrating the air. Induced currents in the electronics, caused directly by the time-varying gradient magnetic fields or the RF pulses, are an additional hazard to the electronic devices themselves. Some materials can also absorb the RF energy causing local tissue heating and even burns if in contact with soft tissue. Hence, the digital audio source, electronics and power

supply that drive the sound system are housed outside the RF screened scanner room to avoid electromagnetic interference with MRI. The electrical signal is then transferred from the audio source to the headphones in the RF screened scanner room using either filters through a filter panel or fibre-optic cable through the waveguide. For the same safety reasons, there are restrictions on scanning people who have electronic listening devices. These include hearing aids, cochlear implants and brainstem implants. Official approval for the manufacture of implant devices requires rigorous testing for susceptibility to electromagnetic fields, radiated electromagnetic fields and electrical safety testing (including susceptibility to electrical discharge). Typically however standard listening devices do not meet the more stringent criteria for compatibility with MR scanning. For the patient, risks include movement of the device and localised heating of brain tissue, whereas, for the device, the electronic components may be damaged. Some implant designs *have* been proven to be MR compatible (e.g. Shellock et al., 1993), but they are not routinely supplied in clinical practice. Given that implanted devices cannot be removed without surgical intervention, clinical imaging research of implantees has generally used other brain imaging methods, namely positron emission tomography (Giraud et al., 2001).

The high levels of scanner noise generated by the flexing of the gradient coils in the static magnetic field can reduce audibility and increase listening effort. Scanner noise increases nonlinearly with static magnetic field strength. For example, comparing scanners from 1 to 3 Tesla indicates a difference in sound level of about 10 dB SPL (Price et al., 2001). The sound level measured in the bore of the scanner is typically 99 dB SPL (98 dB(A)). Clearly, exposure to such an intense sound levels without protection is likely to cause a temporary threshold shift in hearing and tinnitus, and could be permanently damaging over a prolonged stay inside the bore of the scanner (Foster et al., 2000). The simplest way to treat the intense noise is to use ear protection in the form of ear defenders and/or ear plugs. Foam ear plugs can compromise the acoustic quality of the experimental sounds delivered to the subject and so circumaural headsets are preferable. Typically transducers are fitted into sound attenuating earmuffs to reduce the ambient noise level at the subject's ears. Considerable attenuation can be achieved in this manner (e.g., 25 dB of attenuation at 600 Hz rising to 40 dB at 4 kHz, Hall et al., 2009). Even with hearing protection, whenever the scanner noise coincides with the presented sound stimulus it produces changes in task performance and increases the attentional demands of the listening task. The frequency range of the scanner noise overlaps with the range that is crucial for speech intelligibility and so speech experiments can be particularly compromised in the noisy environment. For example, Blackman and Hall (2011) reported that speech intelligibility (measured as the proportion of keywords reported correctly) dropped by about 50% for words that were masked by the scanner noise compared to those that were not masked by the noise.

The high levels of ambient scanner noise can interfere with the patterns of brain activity measured during fMRI. The noise not only activates parts of the auditory brain, but also interacts with the patterns of activity evoked by experimental stimuli. Two novel methods have been developed by the Nottingham group to deal with these problems; sparse temporal sampling (Hall et al., 1999) and active noise reduction (Hall et al., 2009). In sparse sampling, a clustered acquisition of brain slices is combined with a long and fixed (e.g. 10 s) inter-scan interval and the scan acquisition is temporally offset from the presentation of the stimulus of

interest (typically by 8-10 s). Although the scanner noise resulting from the acquisition still evokes an auditory BOLD response, it does not extend across time to the subsequent scan. Work in the mid-90s demonstrated that when the onset of the scan acquisition is synchronized to the offset of an epoch of the stimulus presentation in a sparse sampling paradigm, the activation associated with the experimental sound can be effectively separated from the activation associated with the scanner sound (Hall et al., 1999). Furthermore, because the scanner sound is temporally offset, it does not produce acoustical masking and does not distract the listener. Sparse sampling is often the scanning protocol of choice for identifying auditory cortical evoked responses in the absence of scanner noise. Active noise reduction achieves significant attenuation of the acoustic energy received at the ears. The system reduces the perceived level of the background noise by producing an output ('cancellation') signal that destructively interferes with the scanner sound (i.e. the incident sound wave) at each ear. Precise control over the frequency and phase of acoustic signals presented to participants is achieved through a digital-signal processing system that delivers sound stimuli via a high-fidelity electrostatic headset. Blackman and Hall (2011) evaluated the benefit of active noise reduction by asking whether sound reduction provided sufficient gains in both audibility and sensitivity to sound-related activity to remove the need for sparse temporal sampling. While both sparse sampling and cancellation were found to improve listening quality, these factors did not provide equivalent benefits for auditory fMRI experiments. Cancellation offered small improvements for spatially specific analyses within Heschl's gyrus and planum polare '(regions that are engaged in auditory perception and speech comprehension)' and for reducing some of the extra-auditory activity associated with the effort required for perceptual discrimination in a noisy environment. Nevertheless, sparse acquisition remained the more robust method for detecting auditory cortical activity by providing proper quiet intervals for stimulus presentation.

3. Central auditory processing: Beyond 3 Tesla fMRI

Brain imaging studies in humans are revealing parallels with the functional organization of the auditory brain discovered in electrophysiological studies in animals: sound-level dependencies as well as topographical mapping of stimulus frequencies are observed. This section provides a foundation to the remaining sections in this chapter by describing the BOLD effect and highlighting experiments that investigate the spatial specificity of this effect as a function of the external magnetic field strength and the parameters of the imaging sequence. We consequently describe fMRI experiments that focus on the functional organization of the auditory system. Specifically, we report an experiment on the topographical mapping of sound frequencies in human auditory cortex and discuss common findings and interpretations.

3.1. Characterizing BOLD signal changes at various field strengths

Research systems typically operate at 3 Tesla, but nowadays MRI systems that operate at magnetic field strengths exceeding this field strength are becoming more widely available.

Nottingham University is the home of the first ultra-high field 7 Tesla MRI scanner for human brain imaging in the UK. The key factor for the development of such high field MRI systems is the improvement in intrinsic signal-to-noise ratio and contrast-to-noise ratio with increasing field strength. A simple motor task, for example, elicits a signal change of approximately 1%, 2.5% and 5% for field strengths of respectively 1.5 Tesla, 3 Tesla and 7 Tesla (Van der Zwaag et al., 2009). Figure 1 shows the results for one of our typical auditory tasks acquired at a magnetic field strength of 7 Tesla. In this short experiment, a sound was alternated with silence in a block design. The signal change was 5.2% indicating that the obtained percent signal change is comparable to that obtained in the above motor task. The resulting increased BOLD effect is of great benefit for fMRI basic research studies and also for clinically focussed studies. It can be exploited to improve the spatial resolution and reduces the number of trials required to demonstrate significant levels of activation. An additional effect is the increased spatial specificity of the BOLD effect with increasing field strength. At higher field strengths the T2* time of blood is relatively short causing its signal, originating mainly from the vasculature, to be attenuated relative to that of tissue at the echo times used for BOLD fMRI (Yacoub et al., 2001). The contribution of venous signal to the BOLD effect is therefore reduced at high field strengths, increasing the spatial specificity of the BOLD effect.

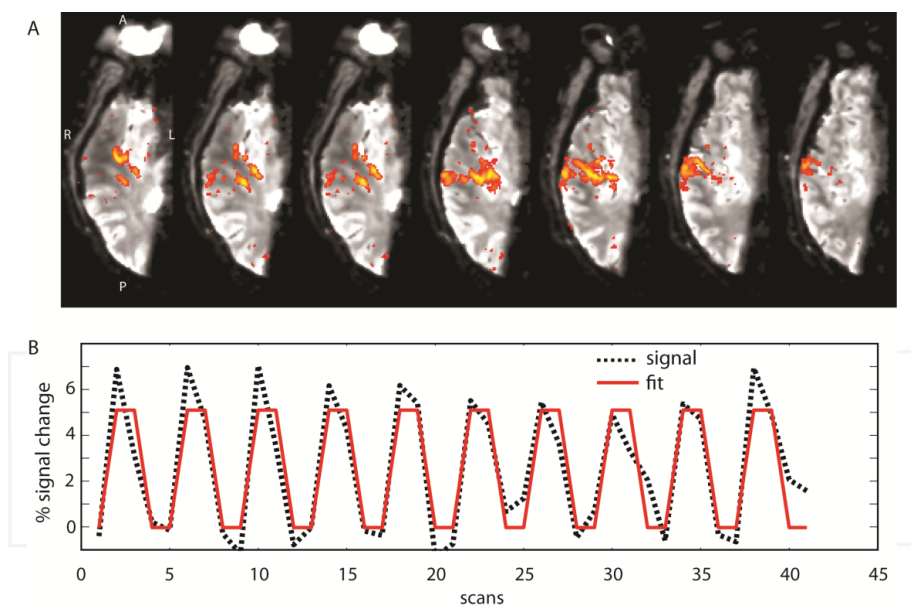


Figure 1. A) Sound-evoked activation maps obtained at 7 Tesla as overlaid on the average EPI image of one subject. The results show the primary auditory cortex, demarcated by the anterior Heschl's sulcus and the posterior Heschl's sulcus, as well as the secondary auditory cortex and higher order areas in the right hemisphere. B) shows the averaged time-course (black) and a linear fit (red) of all the active voxels following a simple block design where blocks of sound were alternated with silence. Abbreviation: A: anterior; P: posterior; R: right, L: left.

3.2. Characterizing the spatial resolution of the BOLD effect

The spatial resolution of the BOLD effect is, compared to most MRI imaging techniques, quite poor. T1-weighted anatomical images can, for example, be easily obtained with an isotropic resolution of well below 1 mm. In contrast, the spatial resolution of the BOLD effect is mostly determined by physiological sources, in the sense that the vascular response to neural activity extends over several millimetres (Logothetis et al., 2001). The BOLD signal originating from small capillaries and surrounding areas is thought to provide good spatial localization for neuronal activation. However, at low and intermediate field strengths, the gradient echo (GE) BOLD effects from large draining veins often contaminate the signal, causing inaccurate localization of the activity and also cause a widening of the point spread function of the BOLD response. GE BOLD is sensitive to extravascular effects around the large vessels while spin-echo (SE) sequences are relatively insensitive to these effects (Duong et al., 2003; Weisskoff et al., 1994). The 180° rephasing pulse in an SE sequence compensates for the constant field heterogeneities to obtain an echo that is weighted in T2 and not in T2*. Spin-echo sequences are therefore more closely related to neuronal activity than GE sequences, although there is still a large contribution of intravascular signal arising from blood. The benefit of high fields (i.e. at field strengths of 3 Tesla and higher) compared to a lower field strength is the reduced T₂ and T₂* of blood relative to that of tissue, reducing the intravascular component even more (Yacoub et al., 2001). However, a major disadvantage with T₂-weighted SE sequences is linked to long inter-scan intervals, resulting in potentially prohibitive acquisition times.

The point spread function describes the response of the MRI scanning to a point source within the brain. Measurements of the point spread function have revealed a full-width at half-maximum (FWHM) of around 2.3 mm tangential to cortical surface of the visual cortex using GE BOLD at 7 Tesla (Shmuel et al., 2007). The FWHM of the point spread function at 7 Tesla is therefore narrower than at 1.5 Tesla (reported at 3.5 mm, Engel et al., 1997) and at 3 Tesla (reported at 3.9 mm, Parkes et al., 2005). Recently, Polimeni et al. (2010) measured the spatial spread of the BOLD response tangential to the cortical surface as a function of cortical depth. Sampling near the pial surface provided the highest signal strength, but it also introduced the most spatial error due to extravascular BOLD effects. Avoiding the surface laminae improved spatial localization considerably, at the cost of sensitivity, implying that optimal spatial resolution in fMRI of the cortex can be achieved using anatomically informed spatial sampling to avoid large pial vessels.

When comparing the point spread function of GE and SE BOLD sequences there is a 13% reduction of the FWHM of the SE sequence, but at a cost of at least 3-fold reduction in contrast to noise ratio (Parkes et al., 2005). fMRI suffers from susceptibility artifacts that are caused by the proximity of air-cavities like the ear canal and nasal cavity causing signal loss and distortion of the images (Ojemann et al., 1997). Many strategies have been proposed to overcome these effects which include the usage of shorter echo times, parallel imaging methods and improved shimming methods. Since static susceptibility artifacts can—at least partly—be refocused using SE techniques, it is less affected by susceptibility artifacts than GE methods and may increase the sensitivity in affected areas (Goense et al., 2008) such as auditory regions in the temporal lobe.

In conclusion, although there is a trade-off between sensitivity and specificity, and the fact that there are still some technical considerations that need to be assessed, most recent imaging literature agree on the advantages of ultra-high field fMRI (i.e. ≥ 7 Tesla), that is, the increased signal-to-noise ratio. This evolution is of special importance for the clinical field in general and the field of auditory research specifically. The next section discusses the application of fMRI to study the functional organization of the auditory cortex.

3.3. Tonotopic organization in the human auditory cortex revealed using fMRI

Many studies have elucidated the functional specialization and hierarchical organization of multiple areas of the auditory cortex in non-human primates using invasive neurophysiological recordings which are obviously not applicable to human studies. A method to map frequency mapping using noninvasive BOLD fMRI in primates is in its early infancy (Petkov, personal communication). At present, there are many applications of BOLD fMRI in experiments on the human auditory system, ranging from the characterization of the effects of sound intensity (Bilecen et al., 2002; Hart et al., 2003), the effects of the side of presentation (Jäncke et al., 2002) to more complex phenomena such as the interaction of scanner noise and sound-evoked responses (Gaab et al., 2007; Hall et al. 1999; Talavage & Edmister 2004) and feature sensitivity and attention modulation (Paltoglou et al., 2011). Mapping one of the most fundamental properties of the auditory system, that of frequency coding, remains elusive and only a few studies have demonstrated a clear topographical arrangement of the response to sound frequency in the auditory pathway. This organization, referred to as 'tonotopy', mirrors the distribution of receptors in the cochlea, with neurons at the base of the cochlea preferentially responding to high frequencies and neurons at the apex responding best to low frequencies (Ehret, 1978). Tonotopy is conveyed up to the level of auditory cortex by fibres in the lemniscal pathway (Figure 3). In the auditory cortex of nonhuman primates, the primary core cortex, consisting of A1, R and RT, exhibit tonotopic gradients that are mirror symmetric to each other (Hackett et al., 2001; Kaas & Hackett 2000; Morel et al., 1993).

Tonotopic organization has been identified in human auditory cortex using a variety of imaging techniques including positron emission tomography (PET) and fMRI. The majority of early studies were based on just two different stimulus frequencies (Bilecen et al., 1998; Lauter et al., 1985; Lockwood et al. 1999; Talavage et al., 2000; Wessinger et al., 1997). From the results a general pattern emerges where high frequencies are represented at the medial end of auditory cortex and low frequencies in the anterior and lateral part of Heschl's gyrus and surrounding areas, mostly as a single low-to-high frequency gradient. More recent studies used more frequencies allowing the identification of more fine-grained frequency gradients. However, the results and interpretations of these studies vary considerably. For example, Langers et al. (2007) reported a single high-to-low gradient extending from posterior medial to anterior lateral auditory areas, similar to earlier studies. Mapping of the left hemisphere at 7 Tesla using surface coils and sparse image acquisition revealed two mirror-symmetric tonotopic maps encompassing three linear gradients of frequency-sensitive BOLD responses in six subjects: (i) one connecting a high-frequency region in Heschl's sulcus with a low-frequency region halfway Heschl's gyrus and (ii) a second connected the same low-frequency region with a high-frequency region near the lateral junction of Heschl's gyrus and the superior

temporal gyrus (Formisano et al., 2003). These results suggest that human auditory cortex conforms to the primate model with two mirror-symmetric tonotopic maps in primary auditory core and belt areas that are joined at a common low-frequency boundary (Petkov et al., 2006). Talavage and colleagues reported three consistent gradients, none of which clearly followed the long (medial-to-lateral) axis of Heschl's gyrus (Talavage et al., 2004). Schönwiesner et al. (2002) argued that the observed frequency selectivity does not necessarily represent frequency gradients but instead represent different functional regions within the auditory cortex (Schönwiesner et al., 2002). Based on this assumption, in combination with the models by Kaas et al. (2000), three recent studies investigated tonotopic mapping and related their findings to anatomical models.

Humphries reported two major mirror-symmetric frequency gradients, oriented roughly perpendicular to Heschl's gyrus, rather than parallel as previously assumed (Humphries et al., 2010). They found a single low-frequency area centered on Heschl's gyrus, bordered anteriorly and posteriorly by two high-frequency areas (planum temporale). This seems very similar to previous findings (Woods et al., 2009). Based on the observed mirror-symmetric frequency gradients, both sets of authors proposed boundaries of regions in human auditory cortex homologous to A1 and R regions in non-human primate cortex. Figure 2 shows the schematic outline of auditory fields as based on electrophysiology in primates and the original group data of both Woods et al. (2009) and Humphries et al. (2010) indicating similar tonotopic maps and a close correspondence between these maps and proposed boundaries as compared to primate data.

A different approach was taken by Striem-Amit et al. (2011), who used phase-encoding (travelling wave) fMRI, a technique previously used to map the visual field onto the visual cortex (Engel et al., 1997; Warnking, 2002). They found up to six mirror-symmetric frequency gradients covering most of Heschl's gyrus and extending to the superior temporal gyrus and superior temporal sulcus (Striem-Amit et al., 2011), beyond the areas previously reported by Woods et al. (2009) and Humphries et al. (2010). Such cochleotopic organization was identified in both left and right hemispheres. The maps of Striem-Amit et al. (2011) demonstrate that tonotopy persists well beyond the auditory core and belt.

The discovery of the tonotopic maps and proposed boundaries between auditory cortical fields might help our understanding of these fields and contributes in defining possible connectivity patterns between these fields. These advances ultimately help us understand the functional consequences of e.g., hearing loss and tinnitus which may affect the function or organization of the auditory cortex (Eggermont, 2006; Komiya & Eggermont, 2000). Both conditions are good examples of auditory disorders with an increasing prevalence due to an aging population.

4. Functional magnetic resonance imaging of tinnitus

4.1. A phantom sound?

Tinnitus is an auditory sensation without the presence of an external acoustic stimulus. In 6-20% of the adult population, tinnitus is a chronic condition and severely disrupts quality

of life in 1-3%. Tinnitus is more prevalent in men than in women and its prevalence increases with advancing age (Axelsson & Ringdahl, 1989). Subjective tinnitus is the most common form of the disorder, but its neural origins remain rather elusive. Like any external acoustic percept, tinnitus is associated with neural activity in the central auditory system. Tinnitus-related activity may arise from abnormal cellular mechanisms in neurons of the central auditory system, or may result from aberrant input from the cochlea or non-auditory structures. Subjective tinnitus is often associated with peripheral hearing loss (Eggermont & Roberts, 2004; Nicolas-Puel et al., 2006) and many patients describe tinnitus as a sound in one or both ears. Therefore, it has been thought for many years that the tinnitus-related neural activity must also originate from the cochlea. Clinical observations however indicate the importance of central mechanisms. In patients that underwent sectioning of the eighth cranial nerve as part of retro-cochlear tumor surgery, tinnitus actually arose in 34% of the cases (Berliner et al., 1992). Surgically severing the connections between the cochlea and the brain has also been applied to provide relief of the tinnitus. This procedure was however not successful in 38-85% of cases (Kaltenbach et al., 2005).

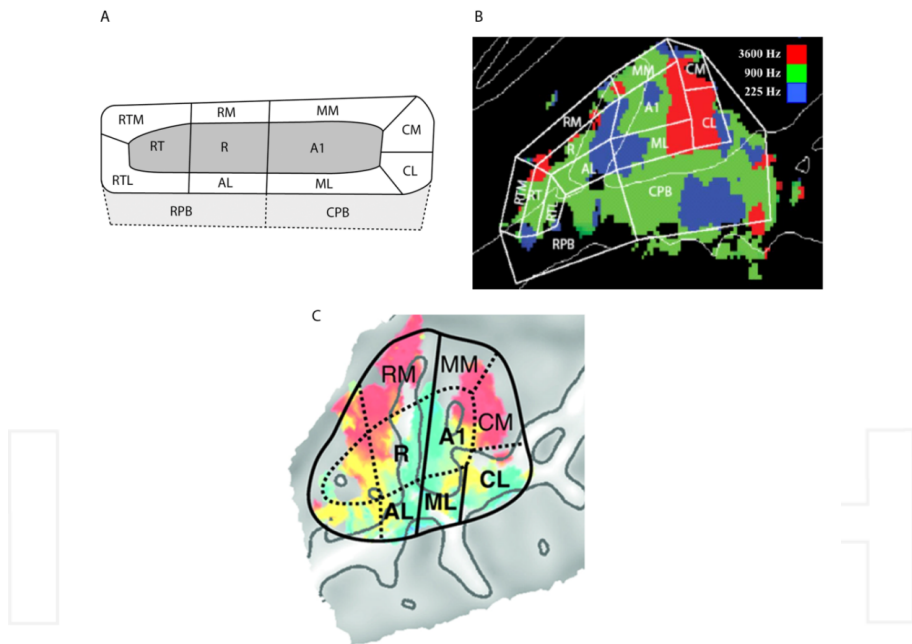


Figure 2. A. Overview of auditory fields in the primate brain showing core areas (A1, R, RT), belt areas (CL, CM, ML, MM, RM, AL, RTL, RTM) and proposed parabelt areas (RPB, CPB); adapted from Kaas et al. (2000). B. The same representation of auditory cortical fields superimposed on tonotopic data in human auditory cortex; adapted from Woods et al., (2009). C. Auditory cortical fields superimposed on tonotopic data; adapted from Humphries et al. (2010). Abbreviations for auditory fields: A1 = primary auditory cortex; R = rostral, T = temporal, M= middle; A = anterior; L = lateral, C=caudal, PB = parabelt.

4.2. Animal studies of tinnitus

Evidence for changes in the firing patterns of neurons in the central auditory system (Figure 3) as a possible substrate of tinnitus is mainly based on animal models. Noise trauma and ototoxic drugs, which are known to cause peripheral hearing loss and tinnitus in humans, result in behavioral responses in animals that seem consistent with the presence of tinnitus. One of these substrates is a change in the spontaneous firing rates of auditory neurons (Eggermont & Roberts, 2004). Since an increased (stimulus-driven) firing rate in auditory neurons typically corresponds to the presence of sound source, an increased spontaneous firing rate could also lead to an auditory percept, i.e., tinnitus. Alternatively, the temporal pattern of spontaneous neural activity could change by increased synchrony of activity across auditory neurons (Noreña & Eggermont 2003; Seki & Eggermont, 2003). The third candidate is a reorganization of the tonotopic map in auditory neurons in the central auditory system (Eggermont 2006; Mühlnickel et al., 1998; Seki & Eggermont, 2003). Although such changes themselves may not directly correspond to tinnitus, they may contribute to abnormal neural activity. For example, cortical reorganization may lead to the over-representation of frequencies corresponding to the frequency at the edge of a high-frequency sloping hearing loss (Eggermont, 2006; Rajan & Irvine, 1998). In other words, auditory-nerve or lower-brainstem neurons that are tuned to an edge frequency could be excessively projected to a region of the auditory cortex. fMRI can be used to identify mechanisms that underlie the generation of tinnitus in humans. Section 4.3 describes the application of fMRI and discusses the outcomes of selected studies.

4.3. Functional magnetic resonance imaging of tinnitus in humans

Although there is much evidence for neural changes based on animal models, there is little corresponding evidence for tinnitus in humans. fMRI is expected to be sensitive to changes in the overall neuronal activity and may reveal changes in neural activity patterns. Yet, given the temporal resolution of typical fMRI studies, changes in synchronous neural activity or spontaneous firing rates may not be apparent from fMRI data. The BOLD signal is a relative measure of tissue properties and so 'activity' cannot be measured directly nor quantified. Instead, fMRI paradigms rely on modulating the hemodynamic response, reflected by neural activity in two (or more) conditions, which allows them to detect differences between states (Ogawa et al., 1990).

Given that tinnitus tends to be a continuous phantom percept, several paradigms have been applied to modulate it in some way. One approach examines sound-evoked responses in tinnitus and control participants, while the second method relies on the ability of a subgroup of people with tinnitus to manipulate their experience by somatic modulation. Examples of include forceful head and neck contractions (Levine, 1999), oral facial movements like jaw clenching or jaw protrusion (Pinchoff et al., 1998), electrical stimulation of the median nerve (Møller et al., 1992) and cutaneous stimulation (Cacace et al., 1999a; 1999b). Other paradigms that could be considered are i) the rapid change of gaze or tonic lateral gaze causing or modulating tinnitus, ii) pharmaceutical interventions that causes a temporal change of the tinnitus (e.g., lidocaine), and, iii) residual inhibition, which refers to the reduc-

tion of the loudness of tinnitus following the offset of an external acoustical stimulus (Roberts, 2007). A review of these paradigms is given by Lanting et al. (2009). Here, we highlight the contribution of fMRI to the current understanding of central mechanisms of tinnitus and explain how interpretations of neuroimaging data may help developing a better understanding of its diverse pathophysiology and of the functional interplay between sensory, cognitive and affective systems.

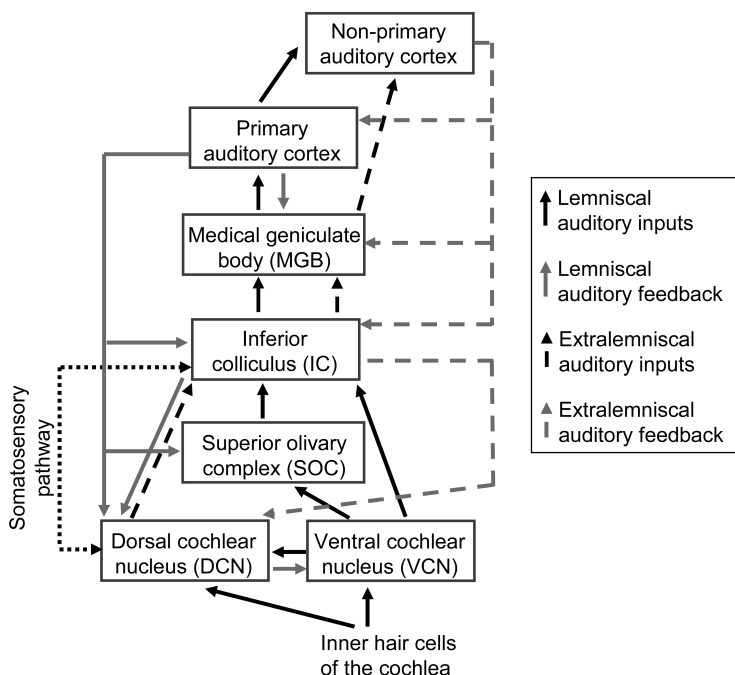


Figure 3. Schematic outline of the auditory system redrawn from Eggermont & Roberts (2004). Inner hairs cells of the cochlea decompose multi-frequency signals into an output that is spatially organised according to frequency (tonotopy). Auditory nerve fibers send inputs to dorsal and ventral cochlear nuclei which both show tonotopic maps. The lemniscal pathway (solid black line) propagates this frequency-specific information throughout all structures. The central auditory system is characterized by strong reciprocal connections (grey lines). The interconnected feedback loops allow the cortex to modulate activity. Changes in dorsal cochlear nucleus, in turn, will directly affect the processing of lemniscal activity at the level of the ventral cochlear nucleus and inferior colliculus. This enables a strong synergy between changes occurring in cortex and brainstem.

4.4. Effects of tinnitus on patterns of sound-evoked activity

Compared to non-tinnitus controls, people with unilateral tinnitus initially appeared to show an abnormally small signal change in the inferior colliculus contralateral to the tinnitus percept, but not ipsilateral (Melcher et al., 2000). These findings were interpreted as evidence that tinnitus corresponds with abnormally elevated baseline neural activity on the

contralateral side. When an external stimulus is presented, the hemodynamic response reaches saturation, resulting in a reduced difference between the 'sound' and 'silence' conditions. A potential confound to these observed patterns of sound-related activity was the influence of ambient background noise. Hence, in a new experiment, this variable was examined by repeating the study with the noisy helium pump either switched on or off (Melcher et al., 2009). All participants had normal hearing. With the pump off, the tinnitus group showed greater stimulus-evoked activation of the inferior colliculus than the non-tinnitus group. With the pump on, the tinnitus group showed reduced activation compared to controls. This result indicates some degree of auditory response saturation in the brains of people with tinnitus. A possible explanation is that a compensatory mechanism of central auditory gain has increased the response amplitudes close to their maximum limit. Lanting et al. (2008) used a sparse temporal sampling paradigm, minimizing the interaction between the scanner noise, the noise of the pump and auditory brain activity. Stimuli consisted of monaural dynamic rippled broadband noise stimuli at two intensity levels (40 dB and 70 dB SPL). Responses were measured at the level of auditory cortex and inferior colliculus of subjects with unilateral tinnitus and near-normal hearing. These were compared with those of people without tinnitus. This study demonstrated abnormally elevated responses in the inferior colliculus in people with tinnitus subjects compared to controls. Figure 4 shows increased sound-evoked responses, a reduced response lateralization (i.e., stimuli presented to the contralateral and ipsilateral ear gave roughly the same signal change) and a disturbed intensity level dependency in subjects with tinnitus compared to subjects without tinnitus at the level of the inferior colliculus (Lanting et al., 2008).

In summary, the first study by Melcher (Melcher et al., 2000) found *decreased* responses in inferior colliculus on the opposite side to the unilateral tinnitus percept, while the other two studies found overall *increased* responses (Lanting et al., 2008; Melcher et al., 2009). At first sight, these three results appear to be contradictory, but a key methodological difference may account for the discrepancy. While Lanting applied sparse temporal sampling, Melcher scanned continuously. Therefore, Melcher's experiments were performed in high levels of ambient scanner noise which may have caused inferior colliculus to respond excessively to this source of background noise and hence reduce the BOLD response to the experimental sound stimuli. The three papers are thus consistent with the interpretation that the inferior colliculus of people with tinnitus displays a disproportionate response to sound, whether it is ambient sound or experimentally controlled sound.

Although sound-evoked responses appear elevated in people with tinnitus, hyperacusis could be an important alternative explanation. This condition is defined as an abnormal sensitivity to sound and is manifest as a diminished level of sound tolerance possibly elevating sound-evoked responses in the auditory brain. Hyperacusis is often co-morbid with tinnitus (Baguley, 2003). A recent study assessed the neural correlates of hyperacusis, recruiting 13 people with tinnitus and 14 people with no tinnitus (Gu et al., 2010). Hyperacusis was assessed using minimum loudness discomfort levels and a validated questionnaire. Severity of sound level tolerance (i.e. hyperacusis) was correlated with elevated activity in the auditory midbrain, thalamus, and primary auditory cortex, despite a fixed sound stimulation level. Sound-evoked activity in the inferior colliculus and medial

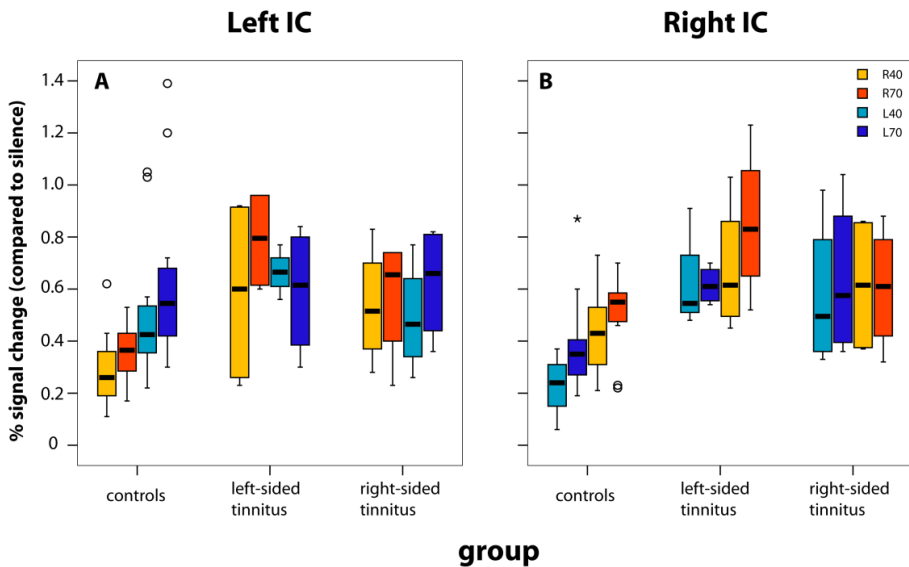


Figure 4. Sound-evoked responses measured in left (A) and right (B) inferior colliculus (IC). The pattern of evoked responses for the side of presentation (left or right ear) and the sound intensity (40 dB and 70 dB SPL) is different for subjects with unilateral tinnitus as compared to controls. Adapted from Lanting et al. (2008)

geniculate body was more associated with hyperacusis than tinnitus, while in primary auditory cortex it was more associated with tinnitus than hyperacusis. Previous findings of increased sound-evoked responses in the inferior colliculus of people with tinnitus (Lanting et al., 2008; Melcher et al., 2009) are most likely to be due to the hypersensitivity to an external sound stimulus than tinnitus per se.

In conclusion, although fMRI has shown general increases in sound-evoked activity in tinnitus, it is more likely to be associated with hyperacusis. Any hypothesized reorganization of tonotopic maps in the auditory cortex has not yet been demonstrated, mostly due to the fact that tonotopic mapping is a relative new field. With the increasing availability of ultra high-field fMRI, this is a promising area for further research.

5. Cross-modal integration in tinnitus

In addition to auditory nerve input, dorsal cochlear nucleus is also innervated by fibers from various parts of the somatosensory system, so this structure is a multi-modal processing station that is considered part of the extralemnisal auditory pathway (Figure 3). Parts of inferior colliculus, medial geniculate body and non-primary auditory cortex are all characterized by sensitivity to somatosensory stimuli (Eggermont & Roberts, 2004). As mentioned in Section 4.3, somatosensory manoeuvres can elicit or modulate tinnitus. Somatic modulation of tinnitus may therefore be considered a special case of multisensory integration—a phenom-

enon, in which one (sensory) modality influences another. The observation that some people with tinnitus can modulate the loudness or pitch of their tinnitus might be explained by changes in normal multisensory integration. Noise-induced hearing-loss, for example, has been reported to alter the normal somatosensory input (Shore et al., 2008). Somatosensory input to the cochlear nucleus increased after hearing loss, changing the balance of somatosensory and auditory input at the level of the brainstem, which in turn might be the neural correlate of somatosensory modulation of tinnitus.

To investigate this proposed model of cross-modal integration, Lanting et al. (2010) studied two groups: people with tinnitus and matched controls. Tinnitus participants were selected according to their ability to change the psychoacoustical characteristics of their tinnitus by jaw protrusion. Unimodal fMRI responses to sound stimuli and jaw protrusion alone were measured, as well as the response obtained in multimodal condition. To minimize motion artifacts, a sparse sampling method (inter-scan interval = 10 s) was used in which the protrusion started 4 s after the beginning of the acquisition and ended 1.5 s before the next acquisition. Since the jaw was always fully relaxed during scan acquisitions, the task did not degrade data quality. Results showed responses to jaw protrusion throughout the central auditory pathway, in both groups. Auditory responses to jaw protrusion presumably account for the modulation of tinnitus by these manoeuvres. Interestingly, responses in cochlear nucleus and inferior colliculus were greater in people with tinnitus than in controls, suggesting an abnormal auditory-somatic interaction in the patient group. This increased sensitivity to somatosensory inputs may correspond to neuroplastic changes, triggered by pathological change of either the somatosensory or auditory input pathways to dorsal cochlear nucleus (see Figure 3 and also Shore, 2011) that, in turn, lead to compensatory shifts in the balance of excitation and inhibition often attributed to tinnitus.

6. Functional and structural assessments of candidature for cochlear implantation

Hearing loss is the most common sensory deficit. Approximately 1.5% of children and 60% of over-70s have hearing loss and, as the average age of the population increases, the social, economic and psychological impact of hearing loss is likely to become more of a burden. Hearing after mild to moderate deafness can be regained through acoustic amplification with a hearing aid, whilst more severe to profound hearing loss can be partially restored by replacing the non-functioning inner ear with a CI.

A CI is a surgically-implanted auditory prosthesis that provides a sense of hearing to deaf individuals. As part of a preoperative clinical evaluation, computerized-tomography (CT) and MRI are both routinely used to assess CI candidates and to aid pre-operative planning and patient counselling. CT provides excellent structural information about bony detail and is useful for assessing congenital malformations that would affect the course of the facial nerve. MRI on the other hand can visualize soft-tissue with high resolution and is used to evaluate the integrity of the auditory nerve and the patency of the cochlea. Traditional CI

candidates were adults with such profound hearing loss they could not benefit from any acoustic hearing. Over the past 25 years CI candidature has been relaxed, to include children and infants in whom auditory deprivation has the most severe developmental consequences. More recently, CIs have been used to treat individuals with some residual acoustic hearing in one or both ears. To date, nearly 200,000 individuals worldwide have been implanted with a CI, approximately half of those being children.

6.1. Prognostic indicators of cochlear implant performance

Although many CI users are able to develop age-appropriate communication and language skills without the need for visual cues, outcomes vary considerably between individuals. A number of factors have been found to correlate with speech outcomes following cochlear implantation (Blamey et al., 1996; Miyamoto et al., 1994). Pre-linguistically deaf adults generally perform more poorly than post-linguistically deaf adults (Busby et al., 1993a; 1993b; Eddington et al., 1978), whilst a long duration of deafness prior to implantation is generally detrimental to performance (O'Donoghue et al., 2000; Sarant et al., 2001). Also, it has been shown that auditory experience can improve clinical performance of cochlear implant users (Blamey et al., 1996; Gantz et al., 1993; Rubinstein et al., 1999). However, individuals with remarkably similar hearing experiences can often have markedly different speech comprehension skills. For example, older pre-linguistically deaf children can occasionally succeed very well in understanding speech, whilst the majority do not (Schramm et al., 2002). Therefore, whilst a number of factors that influence the clinical performance of cochlear implants have been identified, the field currently lacks accurate predictors of cochlear implant performance that can be applied to an individual. Such a prognostic tool, could help direct limited health-care resources towards effective clinical care.

Current national guidelines within the UK suggest that unilateral cochlear implantation is recommended for people with severe to profound hearing loss who do not receive adequate benefit from an acoustic hearing aid. Within this group, simultaneous bilateral cochlear implantation is recommended for i) pre-linguistically deaf children, ii) individuals who are blind, and iii) those who are at risk of cochlear ossification. Therefore, sensitive prognostic tools could be used to mould this crude patient pathway to meet the needs of individual patients, whilst providing realistic indicators of potential outcomes and requirements for rehabilitation.

Behavioural assessments of hearing with a CI are difficult to assess in very young children, as well as individuals with significant physical and/or developmental delay. Therefore, some investigators have focused on developing objective, non-invasive measures of CI function. Electrically-evoked compound action potentials (ECAPs) and electrically-evoked auditory brainstem responses (EABRs) are both routinely used to measure CI function at the level of the auditory nerve and brainstem, respectively. Whilst ECAPs and EABRs are useful clinical tools to ensure that the stimulus levels provided by the CI processor are within the range of perception, there is little evidence to suggest that they correlate well with speech and language outcomes (Miller et al., 2008).

Ultimately, CI users are likely to develop good speech and language skills provided accurate auditory information reaches the auditory cortex. For this reason, attempts have been made to assess functional activation of the auditory cortex with a CI. A number of methods can be used to assess cortical responsiveness to auditory stimulation. However, most of these methods have significant limitations when they are applied to a paediatric CI population.

Earlier in this chapter we discussed the advantages of fMRI in auditory research: a technique that permits the mapping of auditory responses with fine topographic detail, as well multiple observations over time, within both adult and paediatric populations. However, the surgically-implanted magnetic component of a CI device is incompatible with the high magnetic field generated by most MRI scanners. Traditionally, prior to considering MRI, it was necessary to surgically-remove the magnet after cochlear implantation. Recently it has been shown that CI patients can undergo MRI using a low (1.5) Tesla scanner, provided the implanted device is tightly bound before scanning (Crane et al., 2010). Patients in this study received an implant on one side. Although Crane and colleagues observed no magnet displacement whilst visualizing the contralateral- and part of the ipsilateral-internal auditory canal, the artefact surrounding the implanted device (~7x5 cm) precluded functional imaging of the cortex on that side. Similarly, magnetoencephalography (MEG) is limited by the magnetic field associated with current CI devices.

Electroencephalography (EEG) is also used to investigate auditory-evoked cortical potentials. However, the electrical artefact generated by the CI confounds these recordings. Although algorithms have been developed to minimize the effect of CI-generated electrical signals in EEG recordings (Debener et al., 2008), stimulus parameters are generally limited to short-duration sounds such as clicks (Gilley et al., 2006). Responses to longer sounds, including speech and language stimuli, are difficult to extract from the electrical artefact. Functional activation of the auditory cortex can also be assessed using PET that involves the use of ionizing radiation. Due to the cumulative effects of radiation exposure, this technique is not ideal for longitudinal studies, particularly in children.

Sevy et al. (2010) recently demonstrated a relatively novel imaging technique called 'near-infrared spectroscopy' (NIRS) could be used to assess cortical responses to auditory stimulation in children with cochlear implants. NIRS measures relative changes in the tissue contraction, oxy-haemoglobin, deoxy-haemoglobin and total haemoglobin in the cerebral cortex through beaming infra-red light. One of the greatest advantages of this approach is that the optical signals from the auditory cortex are not influenced by the magnetic fields that plague fMRI and MEG recordings. Unlike EEG, NIRS is not affected by CI-generated electrical artifacts. Subjects experience no discomfort with NIRS, as it is a non-invasive test that only requires contacting small optical fibre tips onto the scalp. There are no known risks associated with NIRS. Therefore, unlike PET, it is suitable for multiple measurements in paediatric populations. Although, NIRS provides sufficient resolution to measure evoked responses that are confined to auditory regions of the brain, this spatial resolution (within 1-2 cm of the activated area) is less than that of fMRI. Regardless, compared with alternative techniques, NIRS seems highly suited to assess the responsiveness of the auditory cortex before and after cochlear implantation in paediatric populations.

7. Cross-modal reorganization in the deaf brain

Animal neurophysiology has demonstrated that when sensory neurons lose their input (e.g. vision, touch or hearing) they do not become 'silent'. Instead, they change their responsiveness. In the case of (noise-induced) sensorineural high-frequency hearing loss, neurons previously responding to high frequencies respond to low frequencies (Rajan et al., 1993; Robertson & Irvin, 1989). In the case of complete deafness, neurons become rewired to previously unconnected neurons from another sensory modality (Lomber et al., 2010; Rauschecker et al., 1995).

Cross-modal reorganization refers to the takeover of the processing of sensory information using new cortical pathways. It may be of clinical relevance for hearing-impaired individuals and individuals with a cochlear implant: some people with congenital hearing loss show 'supra-normal' visual abilities (Bavelier et al., 2006; Neville & Lawson, 1987). Furthermore, congenital deafness is known to induce rewiring of inputs within the auditory cortex (Allman et al., 2009; Auer et al., 2007; Finney et al., 2001; 2003; Levänen et al., 1998; Lomber et al., 2010; Nishimura et al., 1999) that plays a vital role in allowing us to process speech and naturally occurring sounds. Recently, Lomber et al. (2010) used cortical cooling techniques in deaf cats to suggest that enhanced visual performance is caused by cross-modal reorganization of the posterior auditory cortex.

Currently, it is not clear whether this rewiring is beneficial to hearing with a cochlear implant (potentially acting as an instructive map to 'train' the reinstated hearing pathways) or detrimental to hearing (by taking away resources from the auditory brain). Regardless, it remains possible that cross-modal reorganization following deafness may prove to be a clinically-useful predictor of performance following cochlear implantation. Lee et al. (2001) used F-18 fluorodeoxyglucose PET to examine resting-state brain activity in pre-lingually deaf individuals. Results indicated an association between hypometabolism in the auditory cortex and the amount of improvement in hearing after cochlear implantation. They speculated that the hypometabolism may be related to cross-modal plasticity and that the individual status of auditory rewiring might be used as an effective predictor of an individual's speech performance following cochlear implantation. More recently, Rouger et al. (2011) demonstrated cross-modal responses in post-lingually deaf adults with cochlear implants engaged in a visual speech reading task using PET brain imaging. Furthermore, they suggested that cross-modal reorganization diminishes in post-lingually deaf adults with CIs with increasing time after implantation (up to at least one year later), towards the levels seen in normal-hearing individuals (Rouger et al., 2011). Doucet et al. (2006) compared cortical evoked potentials between adults with good and poor speech outcomes following cochlear implantation. They found that poor performers exhibited broader, anteriorly-distributed evoked potentials whereas the good performers showed significantly higher amplitudes of the P2 component over the primary visual cortex. Furthermore, Buckley et al. (2006) suggested that cortical responsiveness to visual and auditory evoked potentials accounts for a significant amount of the variability observed in

speech perception performance in adults with cochlear implants with pre-lingual, but not post-lingual, hearing loss. Although, approximately half of cochlear implant recipients are children worldwide, currently, little is known about cross-modal brain reorganization during development.

8. Conclusion and future directions

While the results from a number of functional imaging studies in humans provide preliminary insights into plasticity within the central auditory pathway, more information is needed to understand the patterns of neural reorganization and the mechanisms underpinning those changes. This is an exciting time as novel imaging techniques, such as ultra-high field fMRI and NIRS, open new possibilities for investigating the effects of hearing loss, cochlear implantation and tinnitus on the developing and the mature brain. From our review, three key questions capture avenues of future research that are likely to impact on clinical practice: i) What are the separate effects of deafness, hyperacusis, tinnitus and cochlear implantation on central auditory plasticity, including cross-modal reorganization? ii) What are the perceptual consequences of that reorganization, and iii) How does brain reorganization affect and/or predict treatment outcome?

An ultimate goal for functional imaging is to provide the information necessary for evidence-based healthcare, such as targeting tinnitus treatments to specific neural sites of its generation and predicting outcomes following cochlear implantation. Currently, imaging of the central auditory pathway is not used for routine clinical purposes in Ear, Nose and Throat or Audiology clinics. It is our hope that research using imaging techniques may provide valuable insights into mechanisms underlying tinnitus and the variable speech outcomes following cochlear implantation in humans that may tailor our treatment towards the requirements of the individual.

Author details

Deborah A. Hall¹, Cornelis P. Lanting² and Douglas E.H. Hartley^{1,3}

¹ NIHR Nottingham Hearing Biomedical Research Unit, Nottingham, UK

² MRC Institute of Hearing Research, Nottingham, UK

³ Department of Otorhinolaryngology, Nottingham University, UK

References

- [1] Allman, B.L., Keniston, L.P., & Meredith, M.A. (2009). Adult deafness induces somatosensory conversion of ferret auditory cortex. *Proceedings of the National Academy of Sciences in the United States of America*, 106, 14, pp. 5925-5930.
- [2] Auer, E.T., Bernstein, L.E., Sungkarat, W., & Singh, M. (2007). Vibrotactile activation of the auditory cortices in deaf versus hearing adults. *Neuroreport*, 18, 7, pp. 645-648.
- [3] Axelsson, A., & Ringdahl, A. (1989). Tinnitus--a study of its prevalence and characteristics. *British Journal of Audiology*, 23, 1, pp. 53-62.
- [4] Baguley, D.M. (2003). Hyperacusis. *J R Soc Med*, 96, pp. 582-585.
- [5] Baumann, S., Griffiths, T.D., Sun, L., Petkov, C.I., Thiele, A., & Rees, A. (2011). Orthogonal representation of sound dimensions in the primate midbrain. *Nature Neuroscience*, 14, 4, pp. 31-33.
- [6] Bavelier, D., Dye, M.W.G., & Hauser, P.C. (2006). Do deaf individuals see better? *Trends in Cognitive Sciences*, 10, 11, pp. 512-518
- [7] Berliner, K.I., Shelton, C., Hitselberger, W.E., & Luxford, W.M. (1992). Acoustic tumours: effect of surgical removal on tinnitus. *The American Journal of Otology*, 13, 1, pp. 13- 17.
- [8] Bilecen, D., Scheffler, K., Schmid, N., Tschopp, K., & Seelig, J. (1998). Tonotopic organization of the human auditory cortex as detected by BOLD-FMRI. *Hearing Research*, 126, 1- 2, pp. 19-27.
- [9] Bilecen, D., Seifritz, E., Scheffler, K., Henning, J., & Schulte, A.C. (2002). Amplitude selectivity of the human auditory cortex: an fMRI study. *NeuroImage*, 17, 2, pp. 710-718.
- [10] Blackman, G., & Hall, D.A. (2011). Reducing the effects of background noise during auditory functional magnetic resonance imaging of speech processing: Qualitative and quantitative comparisons between two image acquisition schemes and noise cancellation. *Journal of Speech, Language and Hearing Research*. 54, pp. 693-704.
- [11] Blamey, P., Arndt, P., Bergeron, F., Bredberg, G., Brimacombe, J., Facer, G., Larky, J., Lindstrom, B., Nedzelski, J., Paterson, A., Shipp, D., Staller, S., & Whitford, L., (1996). Factors affecting auditory performance of postlinguistically deaf adults using cochlear implants. *Audiology & Neuro-otology*, 1, 5, pp. 293-306.
- [12] Buckley, K.A., & Tobey, E.A. (2011). Cross-modal plasticity and perception in pre- and postlingually deaf cochlear implant users. *Ear and Hearing*, 32, 1, pp. 2-15.
- [13] Busby, P.A., Tong Y.C., & Clark G.M. (1993a). Electrode position, repetition rate, and speech-perception by early-deafened and late-deafened cochlear implant patients. *The Journal of the Acoustical Society of America*, 93, 2, pp. 1058-1067.

- [14] Busby, P.A., Tong Y.C., & Clark G.M. (1993b). The perception of temporal modulations by cochlear implant patients. *The Journal of the Acoustical Society of America*, 94, 1, pp. 124-131.
- [15] Cacace, A.T., Cousins, J.P., Parnes, S.M., Semenov, D., Holmes, T., McFarland D.J., Davenport, C., Stegbauer, K., & Lovely, T.J. (1999a). Cutaneous-evoked tinnitus. I. Phenomenology, psychophysics and functional imaging. *Audiology & Neuro-otology*, 4, 5, pp. 247-257.
- [16] Cacace, A.T., Cousins, J.P., Parnes, S.M., McFarland, D.J., Semenov, D., Holmes, T., Davenport, C., Stegbauer, K., & Lovely, T.J. (1999b). Cutaneous-evoked tinnitus. II. Review of neuroanatomical, physiological and functional imaging studies. *Audiology & Neuro-otology*, 4, 5, pp. 258-268.
- [17] Crane, B. T., Gottschalk, B., Kraut, M., Aygun, N., & Niparko, J. K. (2010). Magnetic resonance imaging at 1.5 T after cochlear implantation. *Otology Neurotology*, 31, 8, 1215-1220.
- [18] Debener, S., Hine, J., Bleck, S., & Eyles, J. (2008). Source localization of auditory evoked potentials after cochlear implantation. *Psychophysiology*, 45, 1, 20-24.
- [19] Detre, J.A., & Wang, J. (2002). Technical aspects and utility of fMRI using BOLD and ASL. *Clinical Neurophysiology*, 113, 5, pp. 621-634.
- [20] Doucet, M.E., Bergeron, F., Lassonde, M., Ferron, P., & Lepore, F. (2006). Cross-modal reorganization and speech perception in cochlear implant users. *Brain*, 129, pp. 3376-3383.
- [21] Duong, T.Q., Yacoub, E., Adriansy, G., Hu, X.P., Ugurbil, K., & Kim, S.G. (2003). Microvascular BOLD contribution at 4 and 7 T in the human brain: Gradient-echo and spin-echo fMRI with suppression of blood effects. *Magnetic Resonance in Medicine*, 49, 6, pp. 1019-1027.
- [22] Eddington, D.K., Dobbelle, W.H., Brackmann, D.E., Mladejovsky, M.G., & Parkin, J.L., (1978). Auditory prostheses research with multiple channel intracochlear stimulation in man. *The Annals of Otology, Rhinology, and Laryngology*, 87, 6.2, pp. 1-39.
- [23] Edmister, W.B., Talavage, T.M., Ledden, P.J., & Weisskoff R.M. (1999). Improved auditory cortex imaging using clustered volume acquisitions. *Human Brain Mapping*, 7, pp. 89-97.
- [24] Eggermont, J.J. (2006). Cortical tonotopic map reorganisation and its implications for treatment of tinnitus. *Acta Oto-laryngologica. Supplementum*, 556, pp. 9-12.
- [25] Eggermont, J.J., & Roberts, L.E. (2004). The neuroscience of tinnitus. *Trends in Neurosciences*, 27, 11, pp. 676-682.

- [26] Ehret, G., (1978). Stiffness gradient along the basilar membrane as a basis for spatial frequency analysis within the cochlea. *The Journal of the Acoustical Society of America*, 64, 6, pp. 1723-1726.
- [27] Engel, S., Glover, G.H., & Wandell, B. (1997). Retinotopic organization in human visual cortex and the spatial precision of functional MRI. *Cerebral Cortex*, 7, 2, pp. 181-192.
- [28] Finney, E.M., Fine, I., & Dobkins, K.R. (2001). Visual stimuli activate cortex in the deaf. *Nature Neuroscience*, 4, 12, pp. 1171-1173.
- [29] Finney, E.M., Clementz, B.A., Hickok, G., & Dobkins, K.R. (2003). Visual Stimuli activate auditory cortex in deaf subjects: evidence from MEG. *Neuroreport*, 14, 11, pp. 1425-1427.
- [30] Formisano, E., Kim, D.S., Di Salle, F., Van de Moortele, P. F., Ugurbil, K., & Goebel, R. (2003). Mirror-symmetric tonotopic maps in human primary auditory cortex. *Neuron*, 40, 4, pp. 859-869.
- [31] Foster, J.R., Hall, D.A., Summerfield, A.Q., Palmer, A.R., & Bowtell, R.W. (2000). Sound-level measurements and calculations of safe noise dosage during fMRI at 3T. *Journal of Magnetic Resonance Imaging*, 12, pp. 157-163.
- [32] Gaab, N., Gabrieli, J.D.E., & Glover, G.H. (2007). Assessing the influence of scanner background noise on auditory processing. I. An fMRI study comparing three experimental designs with varying degrees of scanner noise. *Human Brain Mapping*, 28, 8, pp. 703-720.
- [33] Gantz, B.J., Woodworth, G.G., Knutson, J.F., Abbas, P.J., & Tyler, R.S. (1993) Multivariate predictors of success with cochlear implants. *Advances in Oto-Rhino-Laryngology*, 48, pp. 153-167.
- [34] Gilley, P. M., Sharma, A., Dorman, M., Finley, C. C., Panch, A. S., & Martin, K. (2006). Minimization of cochlear implant stimulus artifact in cortical auditory evoked potentials. *Clinical Neurophysiology*, 117, 8, 1772-1782.
- [35] Giraud A.L., Truy, E., & Frackowiak, R. (2001). Imaging plasticity in cochlear implant patients. *Audiology & Neuro-otology*, 6, 6, pp. 381-393.
- [36] Goense, J.B.M., Ku, S.-P., Merkle, H., Tolias, A.S., & Logothetis, N.K. (2008). fMRI of the temporal lobe of the awake monkey at 7 T. *NeuroImage*, 39, 3, pp. 1081-1093.
- [37] Gu, J.W., Halpin, C.F., Nam, E.-C., Levine, R., & Melcher, J.R. (2010). Tinnitus, diminished sound-level tolerance, and elevated auditory activity in humans with clinically normal hearing sensitivity. *Journal of Neurophysiology*, 104, 6, pp. 3361-3370.
- [38] Hackett, T.A., Preuss, T.M., & Kaas, J.H. (2001). Architectonic identification of the core region in auditory cortex of macaques, chimpanzees, and humans. *Journal of Comparative Neurology*, 222, pp. 197-222.

- [39] Hall, D.A., Haggard, M.P., Akeroyd, M.A., Palmer, A.R., Summerfield, A.Q., Elliott, M.R., Gurney, E., & Bowtell, R.W. (1999). Sparse temporal sampling in auditory fMRI. *Human Brain Mapping*, 7, 3, pp. 213-223.
- [40] Hall, D.A., Chambers, J., Foster, J., Akeroyd, M.A., Coxon, R., & Palmer, A.R. (2009). Acoustic, psychophysical, and neuroimaging measurements of the effectiveness of active cancellation during auditory functional magnetic resonance imaging. *The Journal of the Acoustical Society of America* 125, 1, pp. 347-359.
- [41] Hart, H.C., Hall, D.A., & Palmer, A.R. (2003). The sound-level-dependent growth in the extent of fMRI activation in Heschl's gyrus is different for low- and high-frequency tones. *Hearing Research*, 179, 1-2, pp. 104-112.
- [42] Howard, M.A., Volkov, I.O., Abbas, P.J., Damasio, H., Ollendieck, M.C., & Granner, M.A. (1996). A chronic microelectrode investigation of the tonotopic organization of human auditory cortex. *Brain Research*, 724, 2, pp. 260-264.
- [43] Humphries, C., Liebenthal, E., & Binder, J.R. (2010). Tonotopic organization of human auditory cortex. *NeuroImage*, 50, 3, pp. 1202-1211.
- [44] Jäncke, L., Wüstenberg, T., Schulze, K., & Heinze, H.J. (2002). Asymmetric hemodynamic responses of the human auditory cortex to monaural and binaural stimulation. *Hearing Research*, 170, 1-2, pp. 166-178.
- [45] Kaas, J.H., & Hackett, T. (2000). Subdivisions of auditory cortex and processing streams in primates. *Proceedings of the National Academy of Sciences of the United States of America*, 97, 22, pp. 11793-11799.
- [46] Kaltenbach, J.A., Zhang, J., & Finlayson, P. (2005). Tinnitus as a plastic phenomenon and its possible neural underpinnings in the dorsal cochlear nucleus. *Hearing Research*, 206, 1-2, pp. 200-226.
- [47] Komiya, H., & Eggermont, J.J. (2000). Spontaneous firing activity of cortical neurons in adult cats with reorganized tonotopic map following pure-tone trauma. *Acta Otolaryngologica*, 120, 6, pp. 750-756.
- [48] Langers, D.R.M., Backes, W.H., & Van Dijk, P. (2007). Representation of lateralization and tonotopy in primary versus secondary human auditory cortex. *NeuroImage*, 34, 1, pp. 264-273.
- [49] Lanting, C.P., De Kleine, E., Bartels, H., & Van Dijk, P. (2008). Functional imaging of unilateral tinnitus using fMRI. *Acta Otolaryngologica*, 128, 4, pp. 415-21.
- [50] Lanting, C.P., De Kleine, E., & Van Dijk, P. (2009). Neural activity underlying tinnitus generation: results from PET and fMRI. *Hearing Research*, 255, 1-2, pp. 1-13.
- [51] Lanting, C.P., De Kleine, E., Eppinga, R.N., & Van Dijk, P. (2010). Neural correlates of human somatosensory integration in tinnitus. *Hearing Research*, 267, 1-2, pp. 78-88.

- [52] Lauter, J.L., Herscovitch, P., Formby, C., & Raichle, M.E. (1985). Tonotopic organization in human auditory cortex revealed by positron emission tomography. *Hearing Research*, 20, 3, pp. 199-205.
- [53] Lee, D. S., Lee, J. S., Oh, S. H., Kim, S. K., Kim, J. W., Chung, J. K., et al. (2001). Cross-modal plasticity and cochlear implants. *Nature*, 409, 6817, 149-150.
- [54] Levänen, S., Jousmäki, V., & Hari, R. (1998). Vibration-induced auditory-cortex activation in a congenitally deaf adult. *Current Biology*, 8, 15, pp. 869-872.
- [55] Levine, R.A. (1999). Somatic (craniocervical) tinnitus and the dorsal cochlear nucleus hypothesis. *American Journal of Otolaryngology*, 20, 6, pp. 351-362.
- [56] Lockwood, A.H. Salvi, R.J., Coad, M.L., Arnold, S.A., Wack, D.S., Murphy, B.W., & Burkard, R.F. (1999). The functional anatomy of the normal human auditory system: responses to 0.5 and 4.0 kHz tones at varied intensities. *Cerebral Cortex*, 9, 1, pp. 65-76.
- [57] Logothetis, N.K., Pauls, J., Augath, M., Trinath, T., & Oeltermann, A. (2001). Neurophysiological investigation of the basis of the fMRI signal. *Nature*, 412, 6843, pp. 150-157.
- [58] Lomber, S.G., Meredith, M.A., & Kral, A. (2010). Cross-modal plasticity in specific auditory cortices underlies visual compensations in the deaf. *Nature Neuroscience*, 13, 11, pp. 1421-U163.
- [59] Lu, H., Golay, X., Pekar, J.J., & Van Zijl, P.C.M. (2003). Functional magnetic resonance imaging based on changes in vascular space occupancy. *Magnetic Resonance in Medicine*, 50, 2, pp. 263-274.
- [60] Mechefske, C.M., Geris, R., Gati, J.S., & Rutt, B.K. (2002). Acoustic noise reduction in a 4 T MRI scanner. *Magnetic Resonance Materials in Physics, Biology and Medicine*, 13, 3, pp. 172-176.
- [61] Melcher, J.R., Sigalovsky, I.S., Guinan, J.J., & Levine, R.A. (2000). Lateralized tinnitus studied with functional magnetic resonance imaging: abnormal inferior colliculus activation. *Journal of Neurophysiology*, 83, 2, pp. 1058-1072.
- [62] Melcher, J.R., Levine, R.A., Bergevin, C., & Norris, B. (2009). The auditory midbrain of people with tinnitus: abnormal sound-evoked activity revisited. *Hearing Research*, 257, 1-2, pp.63-74.
- [63] Merzenich, M.M., Knight, P.L., & Roth, G.L. (1975). Representation of cochlea within primary auditory cortex in the cat. *Journal of Neurophysiology*, 38, 2, pp. 231-249.
- [64] Miller, J. D., Watson, C. S., Kistler, D. J., Wightman, F. L., & Preminger, J. E. (2008). Preliminary evaluation of the speech perception assessment and training system (SPATS) with hearing-aid and cochlear-implant users. *Proc Meet Acoust*, 2, 1, 1-9.

- [65] Miyamoto, R. T., Osberger, M. J., Cunningham, L., Kirk, K. I., Myres, W. A., Robbins, A. M., et al. (1994). Single-channel to multichannel conversions in pediatric cochlear implant recipients. *American Journal of Otology*, 15, 1, 40-45; discussion 45-46.
- [66] Morel, A., Garraghty, P.E., & Kaas, J.H., (1993). Tonotopic organization, architectonic fields, and connections of auditory cortex in macaque monkeys. *The Journal of Comparative Neurology*, 335, 3, pp. 437-459.
- [67] Møller, A.R., Møller, M.B., & Yokota, M. (1992). Some forms of tinnitus may involve the extralemniscal auditory pathway. *The Laryngoscope*, 102, 10, pp. 1165-1171.
- [68] Mühlnickel, W., Elbert, T., Taub, E., & Flor, H. (1998). Reorganisation of auditory cortex in tinnitus. *Proceedings of the National Academy of Sciences of the United States of America*, 95, 17, pp. 10340-10343.
- [69] Neville, H. J., & Lawson, D. (1987). Attention to central and peripheral visual space in a movement detection task: an event-related potential and behavioral study. II. Congenitally deaf adults. *Brain Research*, 405, 2, 268-283.
- [70] Nicolas-Puel, C., Akbaraly, T., Lloyd, R., Berr, C., Uziel, A., Rebillard, G., & Puel, J-L. (2006). Characteristics of tinnitus in a population of 555 patients: Specificities of tinnitus induced by noise trauma. *The International Tinnitus Journal*, 12, 1, pp. 64-70.
- [71] Nishimura, H., Hashikawa, K., Doi, K., Iwaki, T., Watanabe, Y., Kusuoka, H., et al. (1999). Sign language 'heard' in the auditory cortex. *Nature*, 397, 6715, 116.
- [72] Noreña, A.J., & Eggermont, J.J. (2003). Changes in spontaneous neural activity immediately after an acoustic trauma: implications for neural correlates of tinnitus. *Hearing Research*, 183, 1-2, pp. 137-153.
- [73] O'Donoghue, G.M., Nikolopoulos, T.P., & Archbold, S.M. (2000). Determinants of speech perception in children after cochlear implantation. *Lancet*, 356, 9228, pp. 466-468.
- [74] Ogawa, S., Lee, T.M., Kay, A.R., & Tank, D.W. (1990). Brain magnetic resonance imaging with contrast dependent on blood oxygenation. *Proceedings of the National Academy of Sciences of the United States of America*, 87, 24, pp. 9868-9872.
- [75] Ojemann, J.G., Akbudak, E., Snyder, A.Z., McKinstry, R.C., Raichle, M.E., & Conturo, T.E. (1997). Anatomic localization and quantitative analysis of gradient refocused echoplanar fMRI susceptibility artifacts. *NeuroImage*, 6, 3, pp. 156-167.
- [76] Paltoglou, A.E., Sumner, C.J., & Hall, D.A. (2011). Mapping feature-sensitivity and attentional modulation in human auditory cortex with functional magnetic resonance imaging. *The European Journal of Neuroscience*, 33, 9, pp. 1733-1741.
- [77] Parkes, L.M., Schwarzbach, J.V., Bouts, A.A., Deckers, R.H.R., Pullens, P., Kerskens, C.M., & Norris, D.G. (2005). Quantifying the spatial resolution of the gradient echo

- and spin echo BOLD response at 3 Tesla. *Magnetic Resonance in Medicine*, 54, 6, pp. 1465-1472.
- [78] Petkov, C.I., Kayser, C., Augath, M., & Logothetis, N.K. (2006). Functional imaging reveals numerous fields in the monkey auditory cortex. *PLoS Biology*, 4, 7, pp. e215.
- [79] Pinchoff, R.J., Burkard, R.F., Salvi, R.J., Coad, M.L., & Lockwood, A.H. (1998). Modulation of tinnitus by voluntary jaw movements. *The American Journal of Otology*, 19, 6, pp. 785-789.
- [80] Polimeni, J.R., Fischl, B., Greve, D.N., & Wald, L.L. (2010). Laminar analysis of 7T BOLD using an imposed spatial activation pattern in human V1. *NeuroImage*, 52, 4, pp. 1334-1346.
- [81] Price, D.L., de Wilde, J.P., Papadaki, A.M., Curran, J.S., & Kitney, R.I. (2001). Investigation of acoustic noise on 15 MRI scanners from 0.2 T to 3 T. *Journal of Magnetic Resonance Imaging*, 13, pp. 288-293.
- [82] Rajan, R., Irvine, D.R.F., Wise, L.Z., & Heil, P. (1993). Effect of unilateral partial cochlear lesions in adult cats on the representation of lesioned and unlesioned cochleas in primary auditory-cortex. *Journal of Comparative Neurology*, 338, 1, pp. 17-49.
- [83] Rajan, R., & Irvine, D.R. (1998) Neuronal responses across cortical field A1 in plasticity induced by peripheral auditory organ damage. *Audiology & Neuro-otology*, 3, 2-3, pp. 123-144.
- [84] Rauschecker, J.P. (1995). Compensatory plasticity and sensory substitution in the cerebral cortex. *Trends in Neurosciences*, 18, 1, pp. 36-43
- [85] Rauschecker, J.P., & Tian, B. (2000). Mechanisms and streams for processing of "what" and "where" in auditory cortex. *Proceedings of the National Academy of Sciences of the United States of America*, 97, 22, pp. 11800-11806.
- [86] Roberts, L.E. (2007). Residual inhibition. *Progress in Brain Research*, 166, pp.487-495.
- [87] Robertson, D., & Irvine, D.R.F. (1989). Plasticity of frequency organization in auditory-cortex of guinea-pigs with partial unilateral deafness. *Journal of Comparative Neurology*, 282, 3, pp. 456-471.
- [88] Rouger, J., Lagleyre, S., Demonet, J. F., Fraysse, B., Deguine, O., & Barone, P. (2011). Evolution of crossmodal reorganization of the voice area in cochlear-implanted deaf patients. *Human Brain Mapping*, doi: 10.1002/hbm.21331.
- [89] Rubinstein, J.T., Parkinson, W.S., Tyler, R.S., & Gantz, B.J. (1999). Residual Speech recognition and cochlear implant performance: Effects of implantation criteria. *American Journal of Otology*, 20, 4, pp. 445-452.
- [90] Sarant, J.Z., Blamey, P.J., Dowell, R.C., Clark, G.M., & Gibson, W.P.R. (2001). Variation in speech perception scores among children with cochlear implants. *Ear and Hearing*, 22, 1, pp. 18-28.

- [91] Schönwiesner, M., Von Cramon, D.Y., & RübSamen, R. (2002). Is it tonotopy after all? *NeuroImage*, 17, 3, pp. 1144-11461.
- [92] Schramm, D., Fitzpatrick, E., & Seguin, C. (2002). Cochlear implantation for adolescents and adults with prelinguistic deafness. *Otology & Neurotology*, 23, 5, pp. 698-703.
- [93] Seki, S., & Eggermont, J. J. (2003). Changes in spontaneous firing rate and neural synchrony in cat primary auditory cortex after localized tone-induced hearing loss. *Hearing Research*, 180, 1-2, pp. 28-38.
- [94] Sereida, M., Hall, Deborah., Bosnyak, D.J., Edmondson-Jones, M., Roberts, L.E., Adjajian, P., & Palmer, A.R. (2011). Re-examining the relationship between audiometric profile and tinnitus pitch. *International Journal of Audiology*, 50, 5, pp. 303-312.
- [95] Sevy, A.B.G., Bortfeld, H., Huppert, T.J., Beauchamp, M.S., Tonini, R.E., & Oghalai, J.S. (2010). Neuroimaging with near-infrared spectroscopy demonstrates speech-evoked activity in the auditory cortex in deaf children following cochlear implantation. *Hearing Research*, 270, 1-2, pp. 39-47.
- [96] Shellock, F.G., Morisoli, S., & Kanal, E. (1993). MR procedures and biomedical implants, materials, and devices - 1993 update. *Radiology*, 189, 2, pp. 587-599.
- [97] Shmuel, A., Yacoub, E., Chaimow, D., Logothetis, N.K, & Ugurbil, K. (2007). Spatio-temporal point-spread function of fMRI signal in human gray matter at 7 Tesla. *NeuroImage*, 35, 2, pp. 539-552.
- [98] Shore, S.E. (2011). Plasticity of somatosensory inputs to the cochlear nucleus - Implications for tinnitus. *Hearing Research*, 18, 281, 1-2, pp. 38-46.
- [99] Shore, S.E., Koehler, S., Oldakowski, M., Hughes, L.F., & Syed, S. (2008). Dorsal cochlear nucleus responses to somatosensory stimulation are enhanced after noise-induced hearing loss. *The European Journal of Neuroscience*, 27, 1, pp. 155-168.
- [100] Striem-Amit, E., Hertz, U., & Amedi, A. (2011). Extensive cochleotopic mapping of human auditory cortical fields obtained with phase-encoding fMRI. *PLoS One*, 6, 3, pp. e17832.
- [101] Talavage, T.M., Edmister, W.B., Ledden, P.J., & Weisskoff, R.M. (1999). Quantitative assessment of auditory cortex responses induced by imager acoustic noise. *Human Brain Mapping*, 7, 2, pp. 79-88.
- [102] Talavage, T.M, Ledden, P.J, Benson, R.R., Rosen, B.R., & Melcher, J.R. (2000). Frequency-dependent responses exhibited by multiple regions in human auditory cortex. *Hearing Research*, 150, 1-2, pp. 225-244.
- [103] Talavage, T.M., & Edmister, W.B. (2004). Nonlinearity of fMRI responses in human auditory cortex. *Human Brain Mapping*, 22, 3, pp. 216-228.

- [104] Talavage, T.M., Sereno, M.I., Melcher, J.R., Ledden, P.J., Rosen, B.R., & Dale, A.M. (2004). Tonotopic organization in human auditory cortex revealed by progressions of frequency sensitivity. *Journal of Neurophysiology*, 91, 3, pp. 1282-96.
- [105] Van der Zwaag, W., Francis, S., Head, K., Peters, A., Gowland, P., Morris, P., & Bowtell, R. (2009). fMRI at 1.5, 3 and 7 T: Characterising BOLD signal changes. *NeuroImage*, 47, 4, pp.1425-1434.
- [106] Warnking, J. (2002). fMRI retinotopic mapping—step by step. *NeuroImage*, 17, 4, pp. 1665- 1683.
- [107] Weisskoff, R.M., Zuo, C.S., Boxerman, J.L., & Rosen, B.R. (1994). Microscopic susceptibility variation and transverse relaxation: theory and experiment. *Magnetic Resonance in Medicine*, 31, 6, pp. 601-610.
- [108] Wessinger, C.M., Buonocore, M.H., Kussmaul, C.L., & Mangun, G.R. (1997). Tonotopy in human auditory cortex examined with functional magnetic resonance imaging. *Human Brain Mapping*, 5, 1, pp.18-25.
- [109] Woods, D.L, Stecker, G.C., Rinne, T., Herron, T.J., Cate, A.D., Yund, E.W., Liao, I., & Kang, X. (2009). Functional maps of human auditory cortex: effects of acoustic features and attention. *PLoS ONE*, 4, 4, pp. e5183.
- [110] Yacoub, E., Shmuelm A., Pfeuffer, J., Van de Moortele, P.F., Adriany, G., Andersen, P., Vaughan, J.T., Merkle, H., Ugurbil, K., & Hu, X.P. (2001). Imaging brain function in humans at 7 Tesla. *Magnetic Resonance in Medicine*, 45, 4, pp. 588-594.

INTECH

